

University of Louisville

ThinkIR: The University of Louisville's Institutional Repository

Electronic Theses and Dissertations

5-2016

Long term facial alveolar bone changes associated with endosseous implants in the anterior maxilla.

Deepika Joshi

Follow this and additional works at: <https://ir.library.louisville.edu/etd>



Part of the [Oral Biology and Oral Pathology Commons](#)

Recommended Citation

Joshi, Deepika, "Long term facial alveolar bone changes associated with endosseous implants in the anterior maxilla." (2016). *Electronic Theses and Dissertations*. Paper 2421.
<https://doi.org/10.18297/etd/2421>

This Master's Thesis is brought to you for free and open access by ThinkIR: The University of Louisville's Institutional Repository. It has been accepted for inclusion in Electronic Theses and Dissertations by an authorized administrator of ThinkIR: The University of Louisville's Institutional Repository. This title appears here courtesy of the author, who has retained all other copyrights. For more information, please contact thinkir@louisville.edu.

LONG TERM FACIAL ALVEOLAR BONE CHANGES ASSOCIATED WITH
ENDOSSEOUS IMPLANTS IN THE ANTERIOR MAXILLA

By

Deepika Joshi
University of Louisville, 2016

A Thesis

Submitted to the Faculty of the University of Louisville School of Dentistry
In Partial Fulfillment of the Requirements
For the Degree of

Master of Science in Oral Biology

Oral Biology
University of Louisville
Louisville, Kentucky

May 2016

LONG TERM FACIAL ALVEOLAR BONE CHANGES ASSOCIATED WITH
ENDOSSEOUS IMPLANTS IN THE ANTERIOR MAXILLA

By

Deepika Joshi
University of Louisville, 2016

A Thesis Approved on

April 21, 2016

By the following Thesis Committee:

Dr. William C. Scarfe, Thesis Director

Dr. Bruno de Azevedo, Thesis Co-Director

Dr. Bryan T. Harris, Committee Member

Dr. Wei- Shao Lin, Committee Member

DEDICATION

This thesis is dedicated to my parents,

Mr. Ashok Kumar and Mrs. Usha,

my sister Asha.

Without their support, I wouldn't have been able to complete the research.

ACKNOWLEDGEMENTS

I would like to thank my Professor and Thesis Director, Dr. William C. Scarfe, for providing me with the opportunity to work with him in the specialty of oral and maxillofacial radiology, and for his guidance and insight into this research which has made this project very delightful.

Dr. Bruno de Azevedo, Thesis Co-Director, for assisting me in conducting research and gaining insight into the specialty of oral and maxillofacial radiology. His willingness to help at all levels has been inspiring.

Dr. Bryan T. Harris, Thesis Committee Member, for his support and sharing his knowledge of clinical implant dentistry and his eagerness to teach is greatly appreciated.

Dr. Wei- Shao Lin, Thesis Committee Member, for his support and willingness to be a part of my research.

I also wish to acknowledge the contributions of Dr. Dean Morton, for his important inputs on the design of this research in the preliminary stages.

Finally, I wish to thank Dr. Menik Priaminiarti, Fulbright Scholar in the Division of Radiology and Imaging Sciences, Department of Surgical and Hospital Dentistry University of Louisville School of Dentistry from the Department of Dental and Maxillofacial Radiology, Faculty of Dentistry, Universitas Indonesia, for being supportive. Her enthusiasm and commitment made a huge difference in this research.

ABSTRACT

LONG TERM FACIAL ALVEOLAR BONE CHANGES ASSOCIATED WITH ENDOSSEOUS IMPLANTS IN THE ANTERIOR MAXILLA

Deepika Joshi

April, 2016

Aim: To quantify the radiographic presence and thickness of facial alveolar bone (FAB_r) adjacent to implants placed in the anterior maxillary region. Lack of FAB_r may suggest that graft procedures are desirable prior to implant placement.

Material and Methods: With IRB approval, a retrospective analysis of cone beam computed tomographic cross-sectional images of sites with at least one implant in the anterior maxillary region was performed. Details regarding type of implant and location were recorded. FAB_r perpendicular to the long axis each implant was measured at seven levels by two observers independently and means and standard deviations calculated. Inter-observer variability was determined using the Dahlberg formula. The percentage of sites with no FAB_r at each level was compared between sex, implant type and location using Fisher's Exact test ($p \leq 0.05$).

Results: 55% of all implants have no FAB_r at the implant/abutment interface. FAB_r thickness is greater in the apical as compared to the cervical half of all implants (p=0.04). Edentulous spaces restored with tapered implants showed greater radiographic FAB_r in the apical region than with parallel implants (p=0.04).

Conclusion: The majority of implants in the anterior maxilla have no FAB_r long term at the implant/abutment interface. Long term implant FAB_r depends on implant type and may contribute to esthetic compromise.

TABLE OF CONTENTS

	PAGE
DEDICATION.....	iii
ACKNOWLEDGMENTS	iv
ABSTRACT.....	v
LIST OF TABLES.....	ix
LIST OF FIGURES.....	xi
INTRODUCTION AND REVIEW OF THE LITERATURE.....	01
Imaging Evaluation of Potential Implant Sites.....	01
Published Radiographic Imaging guidelines for Implant Site Assessment.....	03
Long Term Success of Dental Implants.....	09
Special considerations for Implant Placement in the esthetic zone.....	11
Optimal Implant Position In the Anterior Maxilla.....	12
Facial Alveolar Bone changes after implant insertion.....	14
Significance of the current study.....	17
HYPOTHESIS.....	18
MATERIALS AND METHODS.....	20
Research Design.....	20
Subject selection.....	21

Sample.....	22
Image formatting and Analysis.....	25
Data collection.....	27
Statistical Analysis.....	28
RESULTS.....	30
Subject Sample	30
Quantitative Assessment.....	33
DISCUSSION.....	43
CONCLUSION.....	47
REFERENCES.....	48
CURRICULUM VITAE.....	52

LIST OF TABLES

TABLE	PAGE
1. Subjective comparison of the relative efficacy of available imaging technologies in providing diagnostic information for implant therapy.....	02
2. Summary of AAOMR (2012) selection criteria recommendations for the use of radiology in dental implantology with emphasis on cone beam computed tomography.....	07
3. Location of identified dental implants according to tooth position.....	31
4. Distribution of implants according to location within the dental arch, sex and type of implant body.....	31
5. Comparison of number of types of implants (tapered and parallel) at different tooth sites.....	32
6. Classification of edentulous spaces in which dental implants are placed.....	32
7. Statistical comparison of average (\pm standard deviation) and range of buccal cortical bone thickness at various distances along the length of implant (n=168) for sex and type of implant.....	34
8. Statistical comparison of buccal cortical bone thickness at various distances along the length of the implant for specific implant sites (n = 168).....	35
9. Number of implants in each type of classification at different tooth sites.....	39

10. Overall Chi Square Test comparing the overall number of implant surfaces covered by bone to those not covered by bone.....	39
11. Distribution of number of implants that showed no corresponding radiographic evidence of bone according to the location at different levels of measurements.....	39
12. Distribution of number of implants that showed no corresponding radiographic evidence of bone according to the type of implant.....	40
13. Distribution of number of implants that showed no corresponding radiographic evidence of bone according to the location and type of implant at different levels.....	41

LIST OF FIGURES

FIGURE	PAGE
1. Flowchart showing application of exclusional and inclusional criteria to CBCT report database to identify potential CBCT image data sets of patients with anterior implants..	24
2. Representative screen shots of codiagnostix software.....	26
3. Screenshot demonstrating corrected cross-sectional image of implant in the right maxillary first premolar region showing no evidence of radiographic bone.....	26
4. Representative screen shot on codiagnostix software showing the measurement of available bab at 7 levels (lv) perpendicular to the long axis of the dental implant.....	29
5. Comparison of mean FAB measurements for each observer.....	33
6. Frequency of tapered and parallel implants in the classification of dental implants restored in edentulous spaces.....	36
7. Frequency of different sets of teeth in each type of dental implants.....	37
8. Frequency of tapered and parallel implants in different sets of anterior teeth.....	38
9. Percentage of cases with no evidence of radiographic bone.....	39

CHAPTER I
INTRODUCTION AND LITERATURE REVIEW

Imaging Evaluation of Potential Implant Sites

Dental implants are currently considered to be the optimal restorative option for the replacement of missing teeth. Pre-treatment surgical planning for placement of dental implants includes evaluation of alveolar bone morphology and bone quality in the residual alveolar ridge and identification of any pathology. Imaging, such as panoramic and intraoral periapical radiography, together with study models of the dental arches, are essential to supplement the clinical assessment of partially edentulous patients in whom dental implants are considered. Jacobs and van Steenberghe (1998) provide an excellent review of pre-CBCT technologies and techniques for implant assessment. Numerous authors have reviewed the efficacy and utility of a various imaging strategies in the assessment of the alveolar ridge at potential implant sites (Frederiksen, 1995; Jacobs and van Steenberghe, 1998; BouSerhal, *et al.*, 2002; Mupparapu and Singer, 2004; Angelopoulos and Aghaloo, 2011).

Scarfe *et al.*, (2012) provide a comparison of the relative clinical efficacy of different dental imaging modalities for the assessment of the residual alveolar ridge in different clinical procedures (Table 1).

Table 1. Subjective Comparison of the Relative Efficacy of Available Imaging Technologies in Providing Diagnostic Information for Implant Therapy (Scarfe, *et al.*, 2012)

<i>Imaging Goal</i>	<i>Specific Objective</i>	<i>Intraoral</i>		<i>Extraoral</i>		
		<i>Pa</i>	<i>Pan</i>	<i>Lat Ceph</i>	<i>Tomography</i>	<i>CBCT</i>
	Vertical bone height	+++	++	+	+++	++++
Morphology of the AR	Horizontal bone width	-	-	-	+++	++++
	Edentulous saddle length	++	++	-	+++	++++
	Bone Quality	+	++	-	++	+++
Orientation of the AR	Cross-sectional topography	-	-	+	+++	++++
				(anterior only)		
Identify limitations of bone volume	Anatomy	+++	++	+	+++	++++
	Pathology	++	+++	+	++	+++
Correlate imaging findings to the prosthetic plan	Radiographic templates	++	++	+	++	++++
	Virtual implant/prosthesis	-	++	-	-	++++
	Image guided surgery	-	-	-	-	++++

pa, periapical radiography; pano, panoramic radiography; lat ceph, lateral cephalometric radiography; Tomo, conventional tomography; CBCT; cone beam computed tomography; -, no/diminutive contribution; +, marginal/minimal contribution; ++, slight/mild contribution; +++, substantial/moderate contribution; +++++, significant/essential contribution.

Numerous authors have proposed surgically desirable parameters of the residual alveolar ridge (RAR) in edentulous areas for implant placement (Greenstein and Cavallaro, 2007; DelBalso, *et al.*, 1994; Greenstein and Tarnow, 2006; Misch, *et al.*, 2005; Misch, *et al.*, 2006; Dawson and Chen, 2009). The most important goal of imaging is to enable translation of prosthetic planning to the surgical site. Numerous software programs are available to assist in the analysis of the residual alveolar ridge using images from CBCT data. Implant planning software provides the clinician with

opportunities to interact with data, and quantify bony anatomic structures associated with the residual alveolar ridge. A variety of DICOM compliant software programs are available.

Published Radiographic Imaging Guidelines for Implant Site Assessment

Several professional organizations have published varying opinions on the use of cross-sectional imaging for implant assessment in dentistry.

The European Association of Osseointegration (EAO) published a position paper on the role of cross-sectional imaging in relation to dental implant planning initially in 2002 (Harris, *et al.*, 2002) and updated it in 2012 (Harris, *et al.*, 2012). The EAO identified four types of clinical situations that might potentially benefit from cross-sectional imaging for diagnosis and treatment planning (Harris, *et al.*, 2012):

1. When the clinical examination and conventional radiography have failed to adequately demonstrate relevant anatomical boundaries and the absence of pathology.
2. When reference to such images can provide additional information that can help to minimize the risk of damage to important anatomical structures and which is not obtainable when using conventional radiographic techniques.
3. In clinical borderline situations where there appears to be limited bone height and/or bone width available for successful implant treatment.
4. Where implant positioning can be improved so that biomechanical, functional, and esthetic treatment results are optimized.

The EAO (Harris, *et al.*, 2012) also indicated that:

“... diagnostic information can be enhanced by use of radiographic templates, computer- assisted planning, and surgical guides.”

In 2012, The International Congress of Oral Implantologists (ICOI) published their position on the role of imaging for implant placement (Benavides, *et al.*, 2012).

They state:

“The literature supports the use of CBCT in dental implant treatment planning particularly in regards to linear measurements, three dimensional evaluation of alveolar ridge topography, proximity to vital anatomical structures, and fabrication of surgical guides.....CBCT should be considered as an imaging alternative in cases where the projected implant receptor or bone augmentation site(s) are suspect, and conventional radiography may not be able to assess the true regional three-dimensional anatomical presentation....”

In 2014, the International Team for Implantology (ITI) published a consensus statement on the use of CBCT in implant dentistry (Bornstein, *et al.*, 2014). They concluded:

1. Current clinical practice guidelines for CBCT use in implant dentistry provide recommendations that are consensus-based or derived from non-standardized methodological approaches.
2. Published indications for CBCT use in implant dentistry vary from preoperative analysis to postoperative evaluation, including complications. However, a clinically significant benefit for CBCT imaging over conventional two-

dimensional methods resulting in treatment plan alteration, improved implant success, survival rates, and reduced 6 complications has not been reported to date.

3. CBCT imaging exhibits a significantly lower radiation dose risk than conventional CT but higher than that of two-dimensional radiographic imaging.
4. Different CBCT devices deliver a wide range of radiation doses.

The ITI further state:

“Substantial dose reduction can be achieved by using appropriate exposure parameters and reducing the field of view (FOV) to the actual region of interest (ROI).”

The American Academy of Oral and Maxillofacial Radiology (AAOMR) published a position statement on selection criteria for the use of cross-sectional imaging in preoperative site assessment for dental implants in 2000 (Tyndall, *et al.*, 2000) and an updated statement in 2012 (Tyndall, *et al.*, 2012). The summary points are:

1. Establish the morphologic characteristics of the residual alveolar ridge such as vertical bone height, horizontal width, and edentulous saddle length. Moderate deficiencies may be corrected by augmentation procedures at the time of the osteotomy. However, severe deficiencies may need prior surgical procedures, such as ridge augmentation, and excessive alveolar bone may require pre-prosthetic or simultaneous alveoloplasty.
2. Determine the orientation of the residual alveolar ridge. The orientation and residual topography should be assessed to determine deviations of the residual alveolar ridge that compromise alignment, particularly in the mandible and anterior maxilla.

3. Identify local anatomic or pathologic conditions within the residual alveolar ridge limiting implant placement. The clinician should be extremely familiar with internal anatomic features of both jaws. Failure to do so can compromise implant body placement or risk involvement of adjacent structures. Often these features are not easily identified or localized by clinical examination or conventional radiographic imaging. Anatomic anomalies may also be present. For example, in the maxilla nasopalatine fossa and canal and nasal fossa are present in anterior region and maxillary sinus floor is present in the posterior region. In mandible, anatomic structures of interest include the mental foramen in the premolar region and the inferior alveolar nerve and the submandibular gland fossa in the posterior molars region.

In 2000, the AAOMR stated:

“After reviewing the current literature, the AAOMR recommends that some form of cross-sectional imaging be used for implant cases and that conventional cross-sectional tomography be the method of choice for gaining this information for most patients receiving implants.”

Since then, the introduction and increased use of maxillofacial CBCT has increased the availability of digital, cross-sectional imaging and expanded imaging clinical applications for dental-implant imaging. In their updated Position Statement, the AAOMR stated (Tyndall, *et al.*, 2012):

“Specifically, the AAOMR recommends that cross-sectional imaging be considered for the assessment of most dental implant sites and that CBCT is the imaging method of choice for gaining this information.”

In addition, the AAOMR provide eleven specific selection criteria recommendations on appropriate imaging (with particular relevance to CBCT) at each phase of dental implant therapy (Table 2).

Table 2. Summary of AAOMR (2012) Selection Criteria Recommendations for the use of radiology in dental implantology with emphasis on cone beam computed tomography

Stage of implant therapy	Recommendation
Initial examination	<ul style="list-style-type: none"> • Panoramic radiography should be used as the imaging modality of choice in the initial evaluation of the dental implant patient. • Use intraoral periapical radiography to supplement the preliminary information from panoramic radiography. • Do not use cross-sectional imaging, including CBCT, as an initial diagnostic imaging examination.
Preoperative site specific imaging	<ul style="list-style-type: none"> • The radiographic examination of any potential implant site should include cross-sectional imaging orthogonal to the site of interest. • CBCT should be considered as the imaging modality of choice for preoperative cross-sectional imaging of potential implant sites. • CBCT should be considered when clinical conditions indicate a need for augmentation procedures or site development before placement of dental implants. • CBCT imaging should be considered if bone reconstruction and augmentation procedures (e.g., ridge preservation or bone grafting) have been performed to treat bone volume deficiencies before implant placement.
Postoperative imaging	<ul style="list-style-type: none"> • In the absence of clinical signs or symptoms, use intraoral periapical radiography for the postoperative assessment of implants. • Panoramic radiographs may be indicated for more extensive implant therapy cases. • Use cross-sectional imaging (particularly CBCT) immediately postoperatively only if the patient presents with implant mobility or altered sensation, especially if the implant body is in the posterior mandible. • Do not use CBCT imaging for periodic review of clinically asymptomatic implants. • Cross-sectional imaging, optimally CBCT, should be considered if implant retrieval is anticipated.

Collectively, the positions of these organizations on the use of dental imaging in implant dentistry are similar. However, slight differences exist between organizations based on the mechanics of the decision process. The AAOMR was clear to state that there

is no perfect imaging available to practitioners, but went on to discuss major advantages of CBCT. Additionally, the AAOMR provided guidelines in a manner that was unlike the EAO and ICOI in that they looked at the implant placement phases and made recommendations on when to use, or not use, CBCT for implant dentistry. The three stages present by the AAOMR are initial exam, preoperative, and postoperative. It was interesting to note that the AAOMR specifically recommends not using a CBCT for initial examination, and to use panoramic and periapical radiographs for any information needed. This recommendation was not provided by either the EAO or ICOI. In preoperative imaging AAOMR assessed benefits of CBCT in respect to the residual alveolar ridge (AR) and a prosthetic plan associated such as digital implant placement, and location of any major anatomical landmarks. Lastly, the AAOMR recommends CBCT for preoperative assessment if bone augmentation procedures are to be performed. Postoperatively, the recommendations were to only use the CBCT if clinical symptoms or implant mobility were seen in the patient. The EAO position provides generic guidelines on when it would be appropriate to use CBCT, specifically in any clinical situations where the practitioner had doubts about the amount of bone available in patients with different levels of edentulism. Additionally, their approach focused on achieving an image with radiation as low as reasonably achievable (ALARA). ALARA was also suggested in AAOMR as well as in ICOI guidelines. The EAO recommends the use of CBCT only if the clinical examination and conventional radiography fails to give the anatomical details. The ICOI suggests using CBCT scans to assess available bone, topography, anatomical structures, pathology, surgical guides, digital implant placement, and communication among all treating practitioners. The ICOI suggestions were different

to AAOMR in respect to support the use of CBCT on individualized patient needs basis; they contend that CBCT is not needed for all pre-surgical implant planning. The ITI guidelines for use of CBCT in implant dentistry are broadly based on three considerations: 1) currently available use guidelines, 2) specific indication and contraindication for use, and 3) the associated relative radiation dose risk (Bornstein, *et al.*, 2014). Although the ITI takes a more affirmative stance for the use of CBCT in implant dentistry, the statement is clear in that decision should be based on any benefit outweighing the risks of radiation. The ITI also conclude that there is a lack of:

“...clear and statistically significant benefit of cross-sectional imaging using CBCT over conventional two dimensional imaging with respect to implant success and damage to inferior alveolar nerve or other vital neurovascular structure in jaws.”

The ITI strongly recommended further research in this area to quantify the clinical efficacy of CBCT imaging.

Long Term Success of Dental Implants

The long-term success of a dental implant and implant supported restoration has significant correlation to its three-dimensional positioning. The surgical considerations incorporating both function and esthetics for optimal implant position in the anterior maxilla (commonly referred to as the esthetic zone) includes (Buser, *et al.*, 2004):

- *Planning and Execution:* Implant therapy in the anterior maxilla is considered an advanced or complex procedure and requires comprehensive preoperative planning and precise surgical execution based on a restoration-driven approach.

- *Patient Selection:* Appropriate patient selection is essential in achieving esthetic treatment outcomes. Treatment of high-risk patients identified through site analysis and a general risk assessment (medical status, periodontal susceptibility, smoking, and other risks) should be undertaken with caution, since esthetic results are less consistent.
- *Implant Selection:* Implant type and size should be based on site anatomy and the planned restoration. Inappropriate choice of implant body and shoulder dimensions may result in hard and/or soft tissue complications.
- *Implant Positioning:* Correct 3-dimensional implant placement is essential for an esthetic treatment outcome. Respect of the comfort zones in these dimensions results in an implant shoulder located in an ideal position, allowing for an esthetic implant restoration with stable, long-term periimplant tissue support.
- *Soft Tissue Stability:* For long-term esthetic soft tissue stability, sufficient horizontal and vertical bone volume is essential. When deficiencies exist, appropriate hard and/or soft tissue augmentation procedures are required. Currently, vertical bone deficiencies are a challenge to correct and often lead to esthetic shortcomings. To optimize soft tissue volume, complete or partial coverage of the healing cap/implant is recommended in the anterior maxilla. In certain situations, a non-submerged approach can be considered.

Recent advances in implant surface technology, surgical techniques, and the intricacies of loading magnitude and timing factors also influence where implants are placed.

Each location in the dental alveolus has unique morphologic characteristics owing to edentulousness and specific regional anatomic features that need to be identified and assessed in the diagnostic and treatment planning phase of dental-implant therapy (Tyndall, *et al.*, 2012).

Special Considerations for Implant Placement in the Esthetic Zone

The replacement of the anterior teeth with dental implant assisted restorations is particularly challenging as a result of elevated esthetic demand (Buser, *et al.*, 2004). The maxillary anterior region often presents both surgical and prosthetic implant-assessment complexities (Buser, *et al.*, 2007). Subsequent to tooth loss, a decrease in the height and/or width of the alveolar process and the development of a labial concavity often necessitate bone augmentation. The morphology and dimension of the nasopalatine canal and the location of the floor of the nasal fossae may also compromise the available bone volume (Ganz, *et al.*, 2011). It has been reported that (Vera, *et al.*, 2012):

- at least 2 mm of facial bone is necessary to resist soft tissue recession, fenestration, and dehiscence.
- There should be at least 1 mm of alveolar bone width on either side of the dental implant in the bucco-lingual dimension

Subsequent to implant insertion, in areas where less than optimal facial bone is evident, recession and potential exposure of implant components is more common, leading to a compromised esthetic outcome. Additionally, in the anterior maxilla the gingival color and contour, along with apico-coronal position of the gingiva on the facial aspect of the definitive restoration relative to the surrounding teeth is critical for long

term esthetic success. Numerous factors have a significant impact on these parameters and therefore the quality of the esthetic outcome as quantitatively determined by the pink or white esthetic score (Belser *et al.*, 2009). These include the gingival phenotype (or biotype), the design and choice of material for the abutment and the prosthesis, the implant design and connection and the height and thickness of the maxillary alveolar facial bone wall in relation to the surface of the dental implant (Kan *et al.*, 2003, Kois *et al.*, 2001). A mean labial gingival recession of 0.5 mm to 1 mm around single anterior implants, partially the result of the bone remodeling, has been reported by numerous authors (Evans, *et al.*, 2008, De Rouck, *et al.*, 2008, Kan, *et al.*, 2003). At the time of abutment connection, a mean reduction in facial bone thickness of 0.4 mm and facial bone height of 0.7 mm have been reported in the maxillary anterior implants (Cardaropoli, *et al.*, 2006). This osseous change resulted in a mean apical displacement of 0.6 mm for the labial soft tissue margin at the 1-year follow-up period (Spray, *et al.*, 2000)

Optimal Implant Position in the Anterior Maxilla

Iatrogenic factors, including compromised implant positioning, also negatively influence the esthetic result (Belser, *et al.*, 2006). Buser, *et al.*, (2006) described the ideal implant placement in the anterior maxilla as being within a 3-dimensional zone defined in the mesio-distal, oro-facial, and apico-coronal dimensions. The authors described this region as the *comfort zone* and further suggested that implants positioned outside of this zone were in ‘danger zones’ where the likelihood of a negative outcome was elevated.

- In the mesio-distal dimension, a minimum of 1 mm should be maintained between

implants and adjacent structures (teeth or other implants). It should be noted, however, that 1.5 mm is more ideal. For implant designs characterized by a tulip form (e.g. Straumann tissue level implants), where the restorative collar of the implant is a greater diameter than the implant body in bone, separating the restorative collar by 1.5 mm from adjacent structures will increase the distance between the implant and adjacent structures at the level of the bone. In summary, the mesio-distal bone volume in the anterior maxilla around single implants should be 1.5 mm, and should be a minimum of 3 mm when separating adjacent implants.

- In the oro-facial dimension, the ideal position of the implant shoulder or restorative margin is influenced by the form of the definitive restoration, as well as the planned emergence profile.
- In the vertical (corono-apical) dimension, the position of the restorative margin should be approximately 2 mm apical to the mid-facial gingival margin of the planned restoration.

The facial danger zone can be particularly problematic, as loss of bone volume has been shown to result in tissue recession and esthetic compromise. Facial danger zones are determined by relating the minimum bone volume required around implants to maintain tissue stability (1.5 mm to 2 mm) to the depth, inclination and orientation of the implant.

Implant placement outside the three dimensional comfort zones and therefore within any danger zone elevates the likelihood of a negative outcome from a functional and/or esthetic perspective.

Facial Alveolar Bone Changes after Implant Insertion

Spray, *et al.*, (2000) investigated the facial bone thickness adjacent to dental implants using direct measurements made with calipers following osteotomy site preparation. The thickness of facial bone was measured at the time of implant placement approximately 0.5 mm below the crest of the bone and then reevaluated at the uncovering appointment (post-placement 3 to 4 months in the mandible and 6-8 months in the maxilla) using a periodontal probe. The authors reported that as facial bone thickness approached 1.8 mm to 2 mm or more, the percentage of implant failures tended to decrease. They also reported that, in general, the implant survival rate tended to increase as the amount of facial vertical bone loss decreased. They reported a mean facial bone thickness of $1.7 \text{ mm} \pm 1.13 \text{ mm}$ and a mean facial vertical bone loss of $0.7 \text{ mm} \pm 1.70 \text{ mm}$. They suggested that 2 mm representing the “critical thickness” of the facial plate may provide optimal implant survival. In addition, the authors reported the prevalence of vertical bone loss as follows: >3 mm loss, 5.25%; 2.1 - 3.0 mm loss, 7.1%; 1.1 - 2.0 mm loss, 15.6%; 0.1 - 1.0 mm loss 27.5%; no change 26.8% and; bone gain 17.7%.

Miyamoto and Obama (2011) investigated the influence of labial alveolar bone thickness and the corresponding vertical bone loss on postoperative gingival recession noted adjacent to anterior maxillary dental implants for two different implant placement techniques: delayed two-stage and immediate placement. Six months subsequent to abutment insertion digital volumes were obtained. The authors concluded that delayed two-stage placement, especially when using a non resorbable membrane, resulted in a greater labial alveolar bone thickness in the cervical region (2.22 mm), less vertical bone resorption (0.13 mm), and less gingival recession (0.06 mm) when compared to

immediate placement that showed 0.48 mm, 3.25 mm, and 0.85 mm, respectively. They also reported that labial bone thickness, as measured on CBCT images, offered an effectual indicator to assess gingival recession in the anterior maxillary region. Clinical relevance and statistical significance of 0.2 mm recession difference is questionable.

Using CBCT data, Roe, *et al.*, (2012) evaluated horizontal and vertical dimensional changes of the facial bone immediately after, and 1 year following, maxillary anterior single immediate implant placement. These authors found the mean vertical facial bone level change was -0.82 mm. They reported the mean facial bone thickness at the level of the implant platform was 1.28 mm, and the mean horizontal facial bone level change was -1.23 mm.

Le and Borzabadi-Farahani (2012) also used CBCT imaging to measure the crestal and mid-implant labial bone thickness (ILBT), and crestal labial soft tissue thickness (CLSTT) around 64 implants (diameter range, 3.3 mm to 4.6 mm) placed in the anterior maxilla. The authors measured at insertion and 4 months post-operatively and found mean (\pm standard deviation) CLSTT and ILBT at crestal and at mid implant levels were 2.45 ± 0.88 mm, 1.79 ± 0.68 mm, and 2.33 ± 1.01 mm, respectively. These authors concluded that there was a significant correlation between the CLSTT and ILBT at the crestal level (Spearman's rho = 0.720) confirming that the position of the mucosal and gingival tissues was heavily influenced by the labial bone thickness.

There is limited data on the long-term alveolar bone stability associated with maxillary anterior implants, and the influence of this on esthetic and functional outcomes. Misje, *et al.*, (2013) followed 18 patients with 22 implants in the anterior maxillary region 12 to 15 years after placement and found mean marginal bone loss to be $1.53 \pm$

0.17 mm measured by digital periapical radiographs. Only two authors have reported facial alveolar bone stability after anterior maxillary implant placement using cone beam computed tomography (CBCT).

Vera, *et al.*, (2012) analyzed 2 groups of patients who received a single tooth in the maxillary anterior or first premolar region either immediate or delayed placement after 12 months. They found a median vertical bone loss distance from the abutment/implant interface of 1.12 mm. At 1 mm apical to the implant/abutment interface they found a horizontal buccal bone loss of 0.62 mm, 0.57 mm and 0.19 mm at the mid-implant and apical regions of the implants respectively. Delayed placement group showed better result in all parameters than immediate placement group.

Long term data was reported recently by Degidi, *et al.*, (2012a) from an analysis of 11 patients who received a single, immediately restored, post-extractive implant in the anterior maxilla after a minimum period of 7 years using computed tomography. They found a vertical mean resorption of 0.6 mm at buccal aspect and an average reduction of buccal plate thickness of 0.3mm from 1.2 mm at the time of surgery to 0.9 mm at the follow-up.

Degidi, *et al.*, (2012b) assessed the buccal bone plate in immediately placed implants restored with Bio-Oss collagen graft. They showed that use of Bio-Oss collagen graft in post extractive sites, there is a mean reduction in the distance between implant surface and outer surface of bone crest was 0.75 ± 0.74 mm representing a mean percent reduction in 24.4%. These results support those of Araujo, *et al.*, (2011) who reported mean buccal vertical resorption of $0.76 \text{ mm} \pm 0.96 \text{ mm}$. However, they contradict those of Hsu, *et al.*, (2010) who state:

“...the placement of implants and Bio-Oss particles into fresh extraction sockets resulted in significant buccal bone loss with lower osseointegration.”

Significance of the Current Study

Limited data is available describing the long term changes in facial alveolar bone (FAB) thickness associated with maxillary anterior implants. The purpose of this study is to quantify changes in FAB thickness long term (> 1 year) associated with implants placed in the anterior maxilla. It is proposed that this information will help identify the proportion of patients who would potentially benefit from bone grafting, and postulate the amount of bone grafting necessary. Should our research data indicate that a preponderance of patients need bone grafting prior to implant placement to optimally position of the implant, then this will support the notion that CBCT imaging is essential prior to implant placement in the anterior maxilla and, during the follow up period.

CHAPTER II

HYPOTHESES

Objectives

The aims of this research are:

1. To retrospectively determine the presence or absence of post-treatment radiographic facial alveolar bone (FAB_r) adjacent functional dental implants at specific levels in the pre-maxilla.
2. To quantify the thickness of post-treatment FAB_r adjacent functional dental implants at specific levels in the pre-maxilla.
3. To determine the influence of implant type (parallel or tapering), sex (male or female) and location (central incisors, lateral incisors, canines, 1st premolars, 2nd premolars) on the presence or absence of FAB_r adjacent functional dental implants at specific levels in the pre-maxilla.

Null Hypothesis

It is hypothesized that:

1. There is no difference between FAB_r adjacent functional dental implants at all specific levels in the pre-maxilla.
2. There is no difference between implant type (parallel or tapering), sex (male or female) and location (central incisors, lateral incisors, canines, 1st premolars, 2nd

premolars) on the presence or absence of FAB_r adjacent functional dental implants at specific levels in the pre-maxilla

CHAPTER III

MATERIALS AND METHODS

Research Design

This investigation is a cross sectional retrospective study based on the radiographic changes of the facial alveolar bone (FAB_r) after implant insertion in the anterior maxillary region in the long term (greater than 1 year). A retrospective audit of CBCT radiologic reports within an imaging database of those referred to the ULSD oral and maxillofacial faculty practice was performed to identify patients with implants in the pre-maxilla. Using implant planning software, measurements of the facial alveolar bone wall thickness on cross-sectional images were made (FAB_r). Two examiners (PI and an oral and maxillofacial radiologist) independently performed measurements perpendicular to the long axis of the implant at seven pre-determined locations. Measurements were compared for inter-examiner reliability using Dahlberg's error. The type of the implant (parallel/tapered) and location was also identified for all implants. Means (and standard deviations) of thickness of the maxillary FAB_r in relation to the surface of the adjacent endosseous dental implant was calculated, frequency distributions generated and comparisons made between dependent variables.

Subject Selection

Institutional Review Board (IRB) approval was granted on March 17, 2014 (IRB # 14.0106). The initial subject sample consisted of all patients in the available CBCT imaging database that had been referred for imaging of either the maxilla or mandible with a previously inserted implant present. Patients had been referred either internally from within the University of Louisville School of Dentistry or externally from practitioners in private dental practice. This CBCT imaging referral service is operated at the faculty private practice by Drs. William C. Scarfe and Bruno Azevedo. Both are board certified and licensed specialists in Oral and Maxillofacial Radiology in the Commonwealth of Kentucky. All CBCT images were acquired using one of the following CBCT devices:

1. i-CAT™ Classic CBCT unit (Imaging Sciences International, Hatfield, PA, USA). The device was operated at 1-3mA and 120 kV using a high frequency, constant potential, and fixed anode with a nominal focal spot size of 0.5mm.
2. i-CAT™ Next Generation (Imaging Sciences International, Hatfield, PA, USA) The device was operated at 1-3mA and 120 kV using a high frequency, constant potential, and fixed anode with a nominal focal spot size of 0.5mm.

Each patient was positioned into the device supported by the constructed plastic head holder. The hard tissue chin of each patient was inserted into the chin holder and vertical and horizontal laser lights on the device used to position the head. The head was oriented such that the mid-sagittal was perpendicular to the floor and the horizontal laser reference was along an imaginary line at the intersection of the porion– orbitale (Frankfurt Horizontal). Resolution was usually set at 0.4mm (i-CAT™ Classic), 0.3mm

(i-CAT™ NG). Scans could be performed at one of three volume sizes; (16 cm diameter x 13.2 cm height; 16 cm diameter x 8 cm height; 16 cm diameter x 13.2 cm x 6 cm height).

Sample

This study involved a retrospective audit of radiologic reports within a CBCT report database (Filemaker Pro v.13, FileMaker Inc., Santa Clara, CA) held within Radiology and Imaging Sciences, Dept. of Surgical/Hospital Dentistry at the University of Louisville School of Dentistry, Louisville, Kentucky. Patient waivers were not necessary, as all personal health information was stripped from the data set collected for analysis.

The following fields of data and associated descriptors were exported into spreadsheet (EXCEL, Microsoft, Redmond, CA):

- **Patient:** Patient A (Pt A), Patient B (Pt B) etc.
- **Gender:** Male/Female
- **Age:** Years and months (e.g. 47.5 yrs, 47 years, 6 months)
- **CBCT Imaging Date** (Date of Cone beam CT imaging): mm/dd/yyyy
- **Reason for referral.** Categorical structured text categorizing the reason that the patient was referred for a CBCT scan. Categories included: Hand Wrist, Implant CBCT, Pathology CBCT, Fracture CBCT, TMJ CBCT, TMJ Tomography, Trauma CBCT, Cleft Lip/Palate, Ortho CBCT, Third Molar CBCT, Cephalometric, Sleep Apnea, Dento/Craniofacial, Impaction CBCT,

Surgical follow up - plates/graft, Surgical follow up – recurrence, Surgical follow up – trauma, Consultation

- **Referring clinician name.** Categorical structured text providing the name of the referring clinician prescribing the CBCT scan.
- **Radiologic findings.** Narrative text data describing any modifications to the scan procedure and describing the imaging features of the condition.
- **Radiologic Impression.** Narrative text data summarizing the primary and incidental or secondary imaging findings.

A total of 5,007 radiographic reports (June 2004 to May 2013) were available.

The following inclusional and exclusional criteria were applied to the CBCT radiologic report database (Fig. 1) in order to identify a sub-sample of subjects who presented with an implant or implants in the anterior maxilla:

1. Scans were sorted according to the **Reason for Referral** field. All reports were excluded except for those where the **Reason for Referral** was *Implant CBCT*. This reduced the potential number of subjects from 5,007 to 4,020.
2. The **Radiologic findings** and **Radiologic Impression** fields in the remaining 4,020 datasets were then queried in their entirety to narrow the sample. Terms such as “*maxilla*”, as well as specific tooth identifiers either by numbers (#4 to #13) or descriptors (e.g. premolar, canine, incisor) were used. This reduced the potential number of subjects from 4,020 to 3,068.
3. Of the remaining reports where potential implants were located in the anterior maxilla, all were read in their entirety to exclude: 1) Patients with complete edentulism and, 2) patients with a history of reported bone grafting.

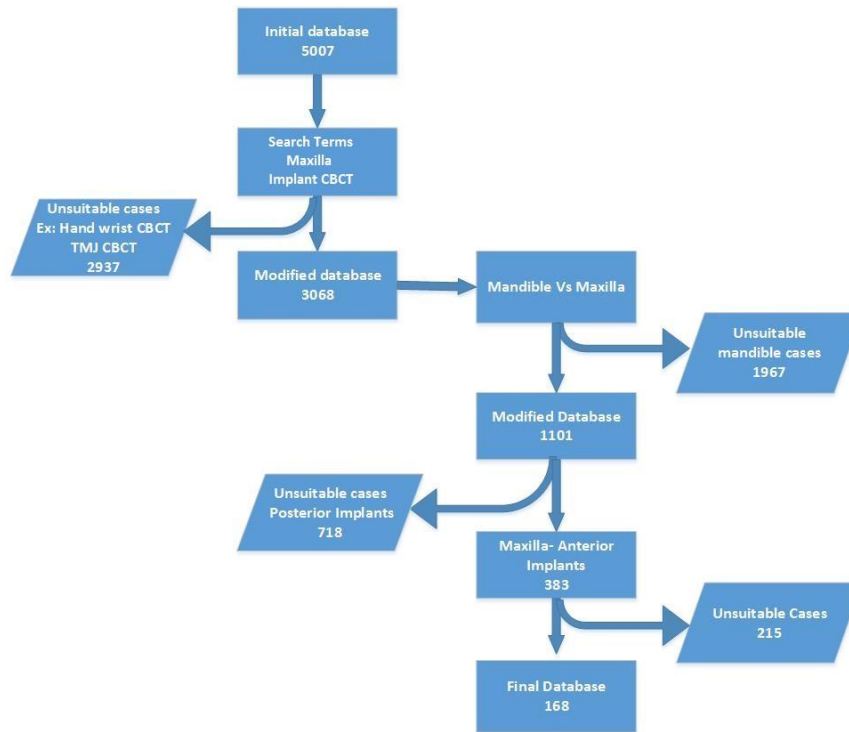


Figure 1. Flowchart showing application of exclusional and inclusional criteria to CBCT report database to identify potential CBCT image data sets of patients with anterior implants.

The CBCT image data sets of patients with anterior implants were then retrieved and curved multi-planar reformatted “panoramic” images generated to provide illustrative representations of the dental status of each patient. The PI viewed each image and only those patients who fulfilled all inclusion/exclusion criteria were then considered as subjects for the study. A total of 108 subjects finally identified who met the inclusional and exclusional criteria having one or multiple implant sites available for assessment in the anterior maxilla.

The CBCT data for each subject was then exported as anonymized DICOM files and codified (Patient A = Pt A, Patient B = P tB, etc.). Reformatted curved linear “panoramic” images were generated and the following observational data collated:

- **Implant Position (Location):** Tooth location designated by Universal tooth numbering system (#4, #5, #6, #7, #8, #9, #10, #11, #12, #13)
- **Implant Position (Area):** Area of mouth (e.g. CI = central incisor; LI = Lateral Incisor; C = canine; PM1 = 1st Premolar; PM2 = 2nd premolar)
- **Type of Implant:** Parallel or tapered

Image Formatting and Analysis

The 108 anonymized CBCT datasets were viewed in implant analysis and virtual planning software (coDiagnostix, version 9.5.2.908, Dental Wings Inc., Montreal, Quebec, Canada). The images were assessed in cross sectional, volumetric rendered images, axial and reformatted panoramic views. After selecting the segmentation option in object tab, the user-defined oblique cut constructs the image in axial, frontal, sagittal and 3D views. (Fig. 2). The focal plane is adjusted so that it passes through the center of the implant. The volumes were reoriented parallel to the long axis of the implants to avoid parallax measurement errors (Fig. 3).

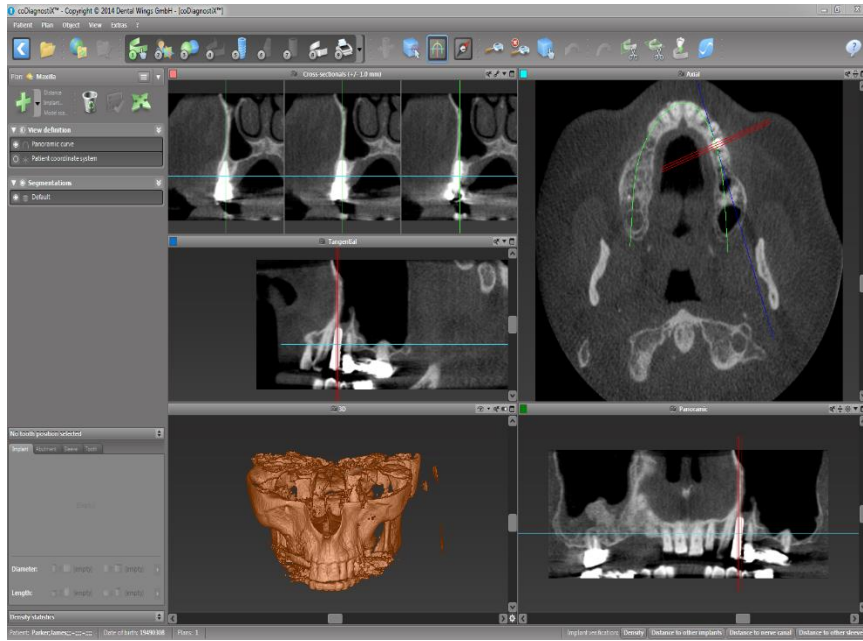


Figure 2. Representative screen shots of coDiagnostix software.

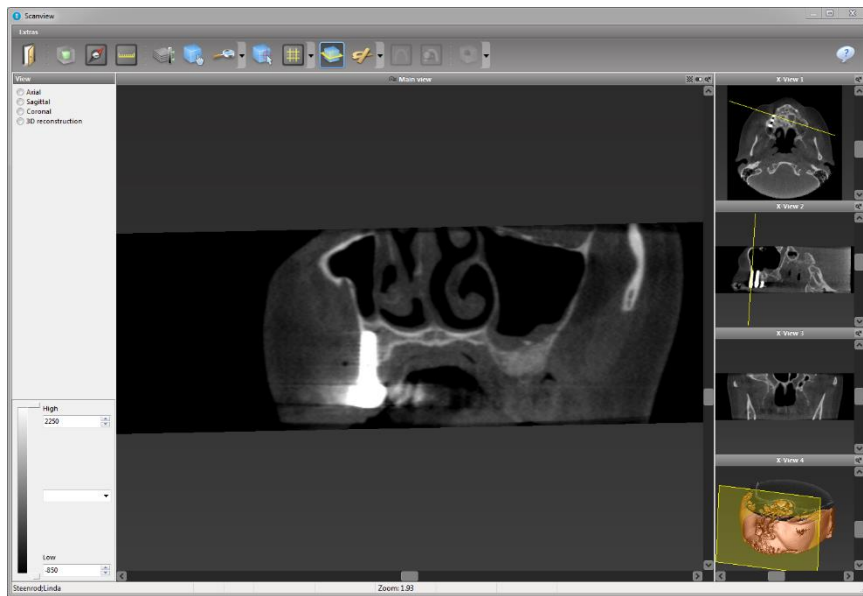


Figure 3. Screenshot demonstrating corrected cross-sectional image of an implant in the right maxillary first premolar region showing no evidence of radiographic bone.

Data Collection

For each site at which an implant was present in the anterior maxilla, two examiners coded as D (PI) and M (MP) measured the independent variable: Horizontal facial alveolar bone thickness (FAB_r) on three separate occasions. These independent readings were designated as S1, S2, S3, D1, D2 and, D3. FAB_r was measured at seven pre-determined locations at various levels of the implant (Fig. 4). These positions are defined as follows:

Level 1: Apex of the implant.

Level 2: Most buccal aspect of the implant in the apical region

Level 3: Midpoint between the apex and middle of the implant

Level 4: mid-implant alveolar bone thickness

Level 5: the midpoint between the abutment and middle of the implant

Level 6: 2.5 mm from the implant/ abutment interface.

Level 7: At the level of the implant/abutment interface

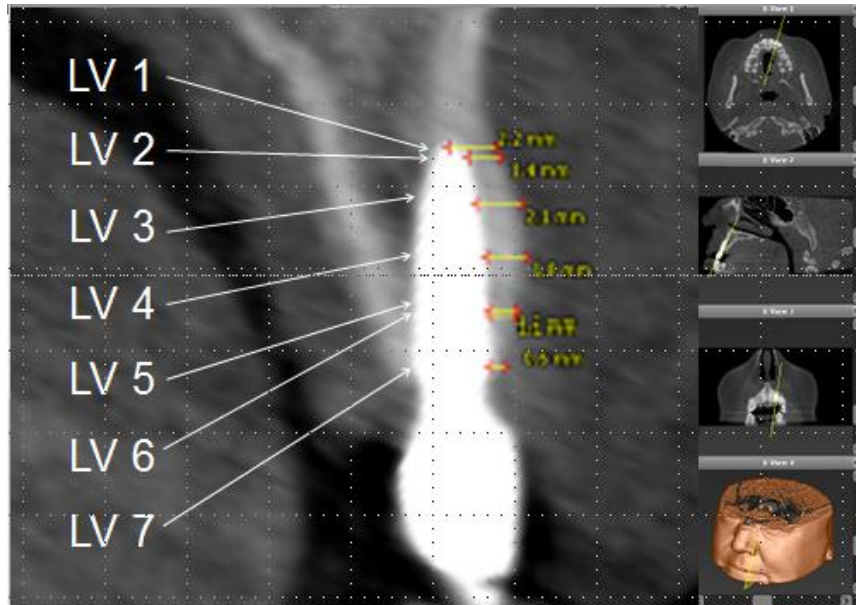


Figure 4. Representative Screen shot on CoDiagnostix software showing the measurement of available BAB at 7 levels (LV 1 to LV 7) perpendicular to the long axis of the dental implant.

Measurements from both observers were averaged for each parameter and the mean used as a measure of the true status.

To avoid intra examiner variability, the measurements were calculated after a gap of one month and the two examiners measured the thickness of the FAB_r independently for inter-examiner reliability.

Statistical Analysis

Selected demographic variables of the patient, the location of the implant, tooth designation were summarized and descriptive statistics developed. Details regarding type of implant and location were recorded. FAB_r perpendicular to the long axis each implant was measured at seven levels by two observers independently and means and standard deviations calculated. Inter-observer variability was determined using the Dahlberg

formula. The percentage of sites with no FAB_r at each level was compared between sex, implant type and location using Fisher's Exact test ($p \leq 0.05$).

CHAPTER IV

RESULTS

The results for the study are provided in the following sections.

1) Subject Sample - Descriptive Statistics

The radiographic records of 5,007 subjects were audited. One hundred and eight ($n_1=108$) subjects were identified with one hundred and sixty-eight ($n_2=168$) dental implants satisfying inclusion criteria for the study. Table 3 shows the location of the dental implants according to tooth position. Table 4 shows distribution of implants according to location within the dental arch, sex and type of implant. Table 5 shows number of types of implants (tapered and parallel) at specific tooth sites.

Table 3. Location of identified dental implants according to tooth position.

<i>Location of Edentulous Space</i>		<i>Total Number of Implants</i>
Second Premolar	Right	17
	Left	23
First Premolar	Right	30
	Left	34
Canine	Right	11
	Left	12
Lateral Incisor	Right	11
	Left	11
Central Incisor	Right	8
	Left	11
	TOTAL	168

Table 4. Distribution of implants according to location within the dental arch, sex and type of implant.

<i>Location</i>	<i>N</i>	<i>Sex</i>		<i>Type</i>	
		<i>Male</i>	<i>Female</i>	<i>Tapered</i>	<i>Parallel</i>
Central	20	10	10	13	07
Lateral	23	06	17	18	05
Canine	23	11	12	18	05
1 st premolar	61	32	29	37	24
2 nd premolar	41	18	23	22	19
Total	168	76	92	108	60

Table 5. Comparison of number of types of implants (tapered and parallel) at different tooth sites.

	Tapered	Parallel	Total
Central Incisors	13	07	20
Lateral Incisors	18	05	23
Canines	18	05	23
1 st Premolars	37	24	61
2 nd Premolars	22	19	41

The implants selected for the study were classified into five categories based on location of implants in relation to the edentulous spaces. Table 6 shows the classification of edentulous spaces in which dental implants were placed (Dawson, *et al.*, 2008).

Table 6. Classification of edentulous spaces in which dental implants are placed (after Chen, *et al.*, 2008)

<i>Classification used in this study</i>	<i>No. of implants in each category</i>
Implants for restoration of single tooth spaces in areas of high esthetic risk (bounded by teeth on either side)	58
Implant(s) for restoration of short edentulous spaces in areas of high esthetic risk	17
Implant(s) for restoration of Prosthetic Replacement in Long edentulous spaces in sites of High Esthetic Risk	18
Implant(s) surrounded by edentulous spaces on either side	13
Implant(s) bounded by teeth on one side and edentulous space on the other side	62
Total	168

The majority of implants were restored in edentulous spaces bound by teeth on one side and edentulous region on the other side. The least number of implants were restored in edentulous spaces bound by no teeth.

2) Inter-observer Measurement Error

Figure 5 compares the measurements of FAB_r for each observer at each level and the average \pm s.d. at each level.

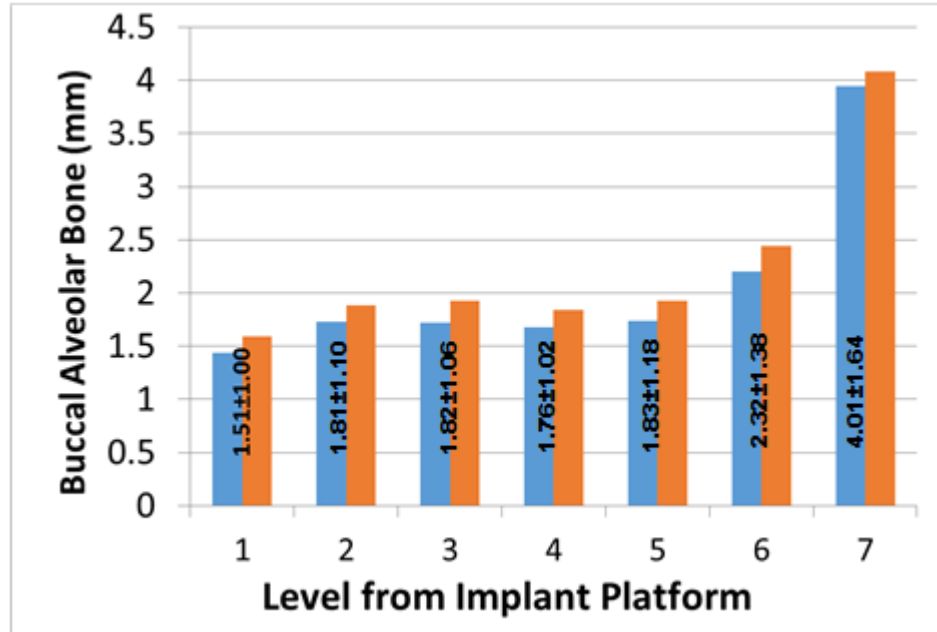


Figure 5. Comparison of mean FAB_r measurements for each observer (orange and blue). Mean and s.d. for each level is centered in the bar.

3) Quantitative Assessment

Table 7 shows the mean FAB_r thickness (\pm s.d.) and statistical comparison between sex and type of implant at each level.

Table 7. Comparison of average (\pm standard deviation) and range of the thickness of the FAB_r at seven levels along the length of dental implant (n = 168) according to sex and type of implant.

<i>Location along Length of Implant (Level)</i>	<i>Male</i>	<i>Female</i>	<i>p</i>	<i>Parallel</i>	<i>Tapered</i>	<i>p</i>	<i>Mean \pm s.d.</i>	<i>Range</i>
Level 1	3.49 \pm 2.23	3.19 \pm .01	.419	2.87 \pm 2.27	3.57 \pm 1.99	0.004*	3.27 \pm 1.97	0-9
Level 2	2.07 \pm 1.82	1.72 \pm 1.46	.144	1.49 \pm 1.67	2.1 \pm 1.58	0.004*	1.87 \pm 1.61	0-8
Level 3	1.59 \pm 1.50	1.14 \pm 1.10	.017*	1.16 \pm 1.41	1.44 \pm 1.25	0.048*	1.34 \pm 1.31	0-7.2
Level 4	1.30 \pm 1.20	0.74 \pm 0.84	.001*	1.04 \pm 1.17	0.97 \pm 0.99	0.846	0.99 \pm 1.05	0-5.1
Level 5	1.10 \pm 1.14	0.62 \pm 0.69	.001*	0.97 \pm 1.02	0.77 \pm 0.91	0.341	0.83 \pm 0.95	0-5
Level 6	1.08 \pm 1.19	0.64 \pm 0.74	.007*	0.99 \pm 0.99	0.76 \pm 0.99	0.319	0.836 \pm 0.99	0-5.2
Level 7	0.67 \pm 1.08	0.48 \pm 0.67	.216	0.70 \pm 0.88	0.4 \pm 0.88	0.234	0.56 \pm .88	0-5

s.d., standard deviation: *, significant difference (**bold**) at the $p < 0.05$ level

Statistical analysis demonstrates: 1) a sex difference in FAB_r thickness at the level of middle half (level 3 to level 5) of the implant with females showing approximately 0.5 mm less coverage, 2) a difference in FAB_r thickness between implant types at the apical 1/3rd region (level 1 to level 3), with tapering implants having approximately 0.5 mm to 0.7 mm greater coverage. Overall, the average FAB_r thickness is less than 1 mm in the cervical half of the implant.

Table 8 shows the mean FAB_r thickness (\pm s.d.) and statistical comparison associated with endosseous implants for specific locations at each level.

Table 8. Statistical comparison of FAB_r thickness at various distances along the length of the implant for specific implant sites (n = 168)

<i>Location along Length of Implant</i>	<i>Central Incisor</i>	<i>Lateral Incisor</i>		<i>Canine</i>		<i>1st Premolar</i>		<i>2nd Premolar</i>	
	Mean ± s.d.	Mean ± s.d.	p	Mean ± s.d.	p	Mean ± s.d.	p	Mean ± s.d.	p
Level 1	2.46 ± 2.39	3.33 ± 1.77	0.135	2.57 ± 2.03	0.986	3.31 ± 1.96	0.071	4.19 ± 2.17	.002*
Level 2	1.42 ± 1.90	1.91 ± 1.43	0.312	1.34 ± 1.48	0.654	1.82 ± 1.51	0.327	2.48 ± 1.75	0.013*
Level 3	1.07 ± 1.36	1.15 ± 1.20	0.700	0.81 ± 1.03	0.440	1.34 ± 1.25	0.386	1.87 ± 1.44	0.012*
Level 4	0.73 ± 0.97	0.67 ± 0.80	0.625	0.67 ± 0.77	0.822	1.04 ± 1.07	0.788	1.42 ± 1.21	0.312
Level 5	0.52 ± 0.69	0.63 ± 0.67	0.505	0.66 ± 0.89	0.350	0.83 ± 0.95	0.650	1.22 ± 1.12	0.272
Level 6	0.58 ± 0.70	0.56 ± 0.66	0.718	0.61 ± 0.86	0.978	0.85 ± 1.04	0.393	1.24 ± 1.15	0.016*
Level 7	0.39 ± 0.70	0.36 ± 0.50	0.916	0.52 ± 0.91	0.586	0.36 ± 0.50	0.430	0.74 ± 1.03	0.172

Statistical analysis demonstrates that, compared to central incisors, FAB_r thickness at all levels is comparable to all teeth, except for the second premolars at the apical half (level 1 to level 3) and 2.5 mm from the implant platform (level 6) where there is significantly more bone coverage.

Figure 6 shows the frequency of tapered and parallel type of implants according to category of edentulous space. The most common situation was tapered implants in Type 5 edentulous space. There are more tapered than parallel implants at each site. The first premolar region had the highest total number of implants.

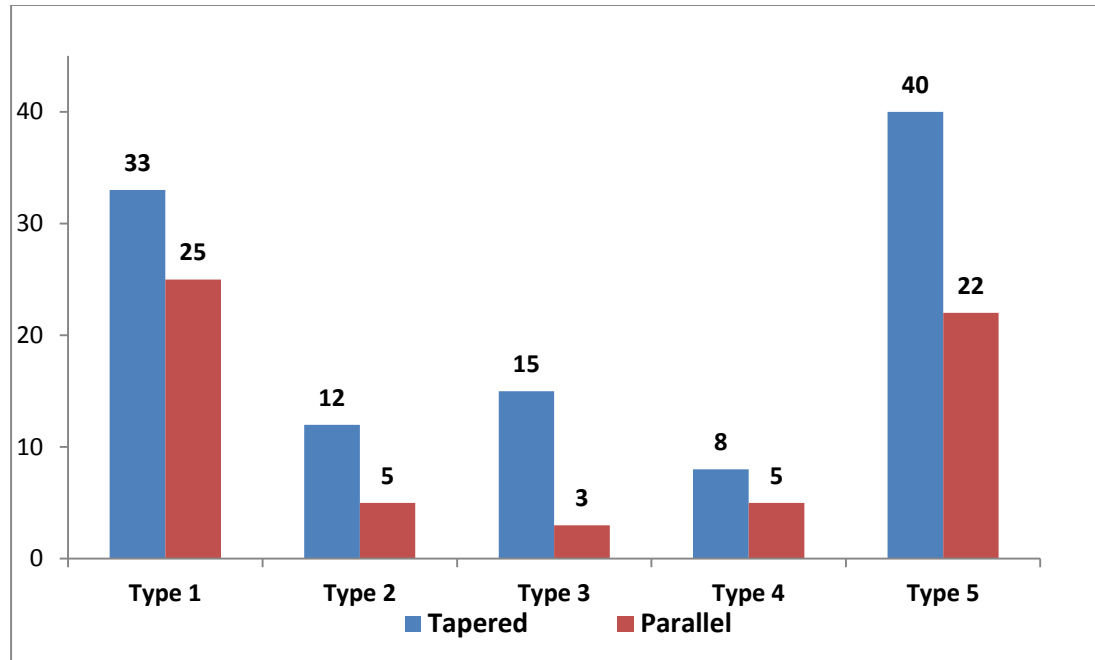


Figure 6. Frequency of tapered and parallel implants according to type of edentulous space restored [Type 1:Implants for restoration of single tooth spaces in areas of high esthetic risk (bounded by teeth on either side); Type 2, Implant(s)for restoration of short edentulous spaces in areas of high esthetic risk; Type 3, Implant(s) for restoration of Prosthetic Replacement in Long edentulous spaces in sites of High Esthetic Risk; Type 4, Implant(s) surrounded by edentulous spaces on either side; Type 5, edentulous space bound by teeth on one side and edentulous area on the other.]

Table 9 shows the distribution of edentulous spaces according to location. Note that no implants were placed into Type 4 edentulous space at the incisor location. Most implants were placed in the premolar region into type 5 edentulous space. Figure 7 is a graphical representative of Table 9.

Table 9. Number of Implants in each type of classification at different tooth sites.

<i>Tooth Location</i>	<i>Type 1</i>	<i>Type 2</i>	<i>Type 3</i>	<i>Type 4</i>	<i>Type 5</i>	<i>Total</i>
Incisors	26	1	10	0	4	41
Canines	7	2	3	4	7	23
Premolars	25	14	5	9	51	104

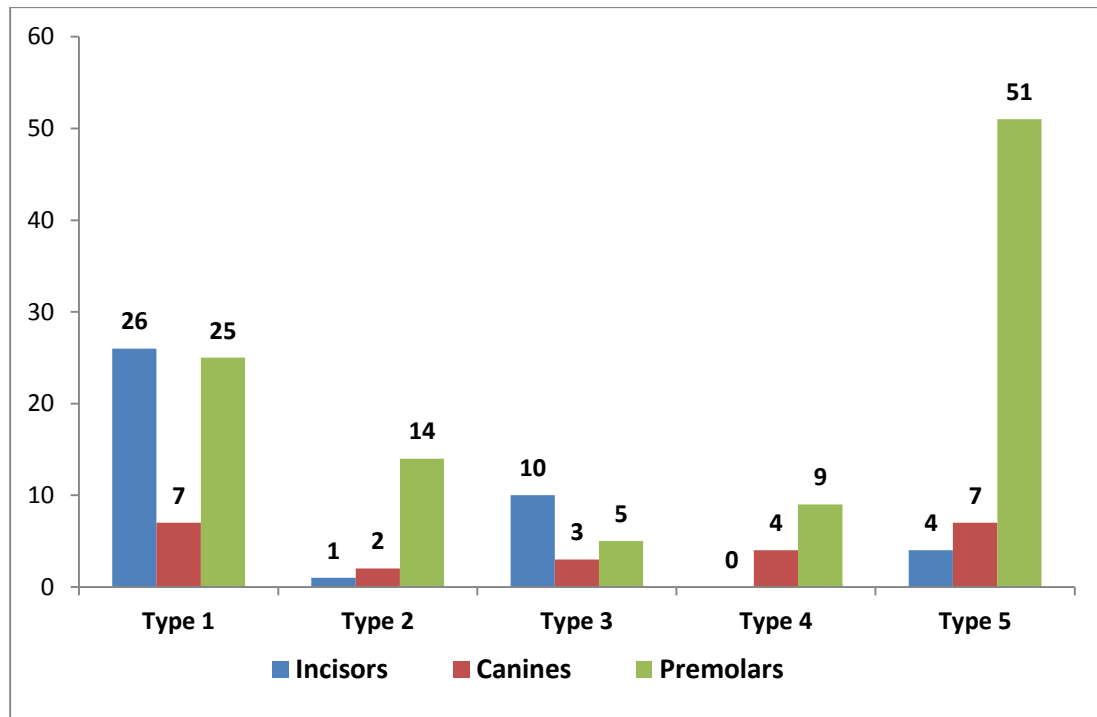


Figure 7. Frequency of different sets of teeth in each type of dental implants.

Figure 8 shows the distribution of type of implant in anterior teeth according to location. Most implants were placed in the premolar region and, of these, the majority were tapered. The least number of implants were placed in the canine region and were parallel.

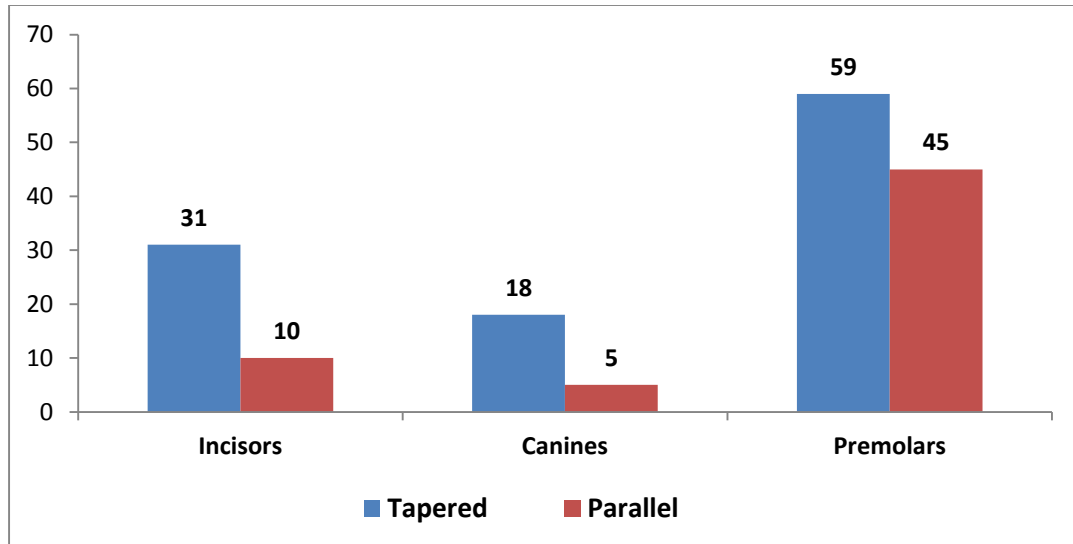


Figure 8. Frequency of tapered and parallel implants at different locations.

Figure 9 shows the percentage of edentulous spaces restored with implants that showed no evidence of FAB_r at each level. There is a high percentage (approximately 55%) of implants in the pre-maxilla that demonstrate no alveolar crestal bone at the level of the implant platform (level 7).

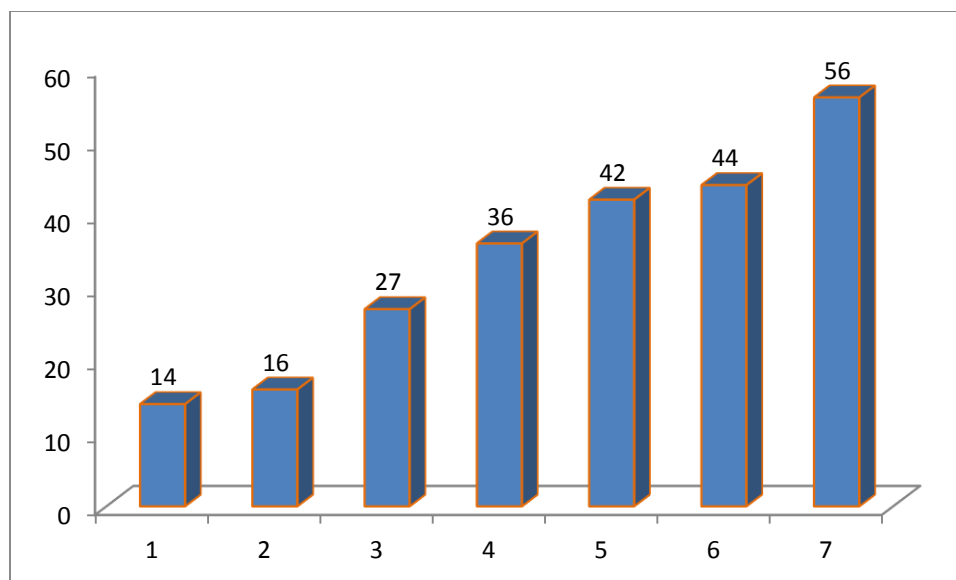


Figure 9. Percentage of cases with no evidence of radiographic bone.

Table 10 shows the overall Chi squared analysis comparing the overall number of implant surfaces covered by bone to those not covered by bone indicating that type of implant and location are dependent on each other.

Table 10. Overall Chi Square Test comparing the overall number of implant surfaces covered by bone to those not covered by bone

	Value	df	Significance (2- sided)
Pearson Chi square	17.219	6	0.009
Likelihood Ratio	16.904	6	0.010

Table 11 shows the number of implants at each level where there is no FAB_r according to tooth location. No differences between percentage of FAB_r implants were found at any level.

Table 11. Distribution of number of implants that showed no corresponding radiographic evidence of bone according to the location at different levels of measurements.

<i>Tooth Location</i>	<i>Level I</i>	<i>Level II</i>	<i>Level III</i>	<i>Level IV</i>	<i>Level V</i>	<i>Level VI</i>	<i>Level VII</i>
Central Incisors	4	4	6	9	11	10	13
Lateral Incisors	2	4	6	10	9	10	12
Canines	4	4	8	9	10	12	15
1 st Premolars	9	11	18	22	27	28	35
2 nd Premolars	2	2	5	9	12	12	17

Table 12 shows the number of implants at each level where there is no FAB_r according to type of implant. FAB_r is significantly less in the apical region (Level 1 to level 3) compared to tapering implants

Table 12. Distribution of number of implants (percentages) that showed no corresponding radiographic evidence of bone according to the type of implant.

<i>Type of Implant</i>	<i>Level I</i>	<i>Level II</i>	<i>Level III</i>	<i>Level IV</i>	<i>Level V</i>	<i>Level VI</i>	<i>Level VII</i>
Parallel (60)	13 (21.6%)	14 (23.3%)	21 (35%)	22 (36.6%)	23 (38.3%)	22 (36.6%)	31 (51.6%)
Tapered (108)	8 (7.4%)	11 (18.3%)	22 (20.3%)	37 (34.2%)	46 (42.5%)	50 (46.2%)	61 (56.4%)
Fisher's Exact test	X ² = 7.17 p=0.013	X ² = 5.26 p=0.025	X ² = 4.33 p=0.043	X ² = 0.09 p=0.086	X ² = 0.28 p=0.062	X ² = 1.46 p=0.256	X ² = 0.36 p=0.62

Table 12 shows the overall distribution of number of implants with no FAB_r according to the location and type of implant at different levels.

Table 13. Distribution of number of implants that showed no corresponding radiographic evidence of bone according to the location and type of implant at different levels.

<i>Location of Implants</i>	<i>Level I</i>		<i>Level II</i>		<i>Level III</i>		<i>Level IV</i>		<i>Level V</i>		<i>Level VI</i>		<i>Level VII</i>	
	<i>*P</i>	<i>*T</i>	<i>P</i>	<i>T</i>	<i>P</i>	<i>T</i>	<i>P</i>	<i>T</i>	<i>P</i>	<i>T</i>	<i>P</i>	<i>T</i>	<i>P</i>	<i>T</i>
Central Incisors	2	2	2	2	2	4	2	8	3	8	2	8	4	9
Lateral Incisors	2	0	2	2	2	4	2	7	1	8	2	9	2	10
Canines	1	3	1	3	3	5	3	6	3	7	3	9	3	12
1 st Premolars	6	3	7	4	11	7	11	11	11	16	10	18	14	19
2 nd Premolars	2	0	2	0	3	2	4	5	5	7	5	6	8	11
Total	21		25		43		59		69		72		92	

*P= Parallel *T= Tapered

CHAPTER V

DISCUSSION

In this study, the radiographic thickness of facial alveolar bone (FAB_r) adjacent to implants placed over a year was measured at edentulous sites in the anterior maxilla (second premolar anteriorly). This study was limited to implants in this region because they are often placed in areas of high esthetic value. Long term esthetic success of dental implants in this region depends on the apico-coronal position of the gingiva (Belser *et al.*, 2009), which is, in part determined by the height and thickness of the maxillary alveolar (FAB_r) in relation to the surface of the dental implant (Kan *et al.*, 2003; Kois *et al.*, 2001; Spray, *et al.*, 2000; Miyamoto and Obama, 2011). In these regions, adequate bone volume should be present in peri-implant tissues. While 2 mm of FAB_r has been reported as the “critical thickness” to provide optimal implant survival and esthetics (Spray, *et al.*, 2000). We found the majority of previously placed implants (approximately 55%) to have no radiographic discernible facial alveolar bone coverage at the moist crucial level of the implant – at the implant/abutment interface. We also found FAB_r at this level to increase from a mean of 0.39 ± 0.70 mm at the central incisor region to 0.74 ± 1.03 mm at the second premolar region. This is substantially lower than the mean facial bone thickness of 1.28 mm at the same level reported by Roe, *et al.*, (2012) for implants placed 1 year

following maxillary anterior single immediate implant placement and 1.79 ± 0.68 mm reported by Le and Borzabadi-Farahani (2012) 4 months post-operatively.

Unlike previous studies, we also measured FAB_r along the length of the implant. Overall we found more bone coverage at the apical half of the implant as compared to the cervical half. In addition, we found significantly more FAB_r in the apical 1/3rd region with tapering implants than parallel implants (range, 0.3mm to 0.6mm). Overall, the average FAB_r is less than 1 mm adjacent over the cervical half of implants, irrespective of type. Interestingly, we found a sex difference in the amount of FAB_r covering implants in the middle third of the implant with significantly less bone (approximately 0.5mm less) for females. With no current literature to support our position, we postulate that there may be an anatomic difference between males and females in the shape of the buccal cortical concavity corresponding to this region that would explain this result. This is supported, in part, by our finding that in the second premolar region, where there is minimal anatomic buccal concavity that there is significantly more FAB_r covering the apical half and at 2.5 mm from the implant platform than compared to the central incisors.

We also found a significantly great percentage of parallel implants with no FAB_r covering the apical half than tapering implants. This is to be expected because of the reduced diameter of tapering implants in this region but also because often, tapering implants selected instead of parallel implants at the same specific site because they have a reduced diameter.

There are specific limitations to the clinical inference from the results of the study related to the nature of the data and limitations of CBCT

This is a retrospective study identifying implants placed at specific sites on a cohort of patients who presented for imaging for a non-specific reason. The “history” of the included sample of implants was completely unknown, including the date of insertion. An assumption of “long term” (greater than 1 year) was made based on the fact that all implants were restored. In addition, the type (tissue level/bone level), diameter and length of the implants restored in the edentulous spaces was unknown. Implant width (diameter) as well as period of insertion could potentially have been dependent variables.

CBCT imaging has specific limitations in regard to measurement accuracy and ability to image FAB_r. All images were acquired at a nominal voxel size of 0.4mm (CAT™ Classic) or 0.3mm (i-CAT™ NG). This implies that technical error is approximately 0.8mm or 0.6mm respectively (2 adjacent voxels). Beam hardening artifacts from high density titanium implants could have also reduced the visibility of the FAB, resulting in an overestimation of number of sites without coverage or measurement underestimation of thickness.

Our study highlights the importance of pre-treatment evaluation of alveolar bone volume along with appropriate selection of implant type and size to optimize facial bone coverage. Despite acknowledged CBCT measurement and visualization limitations, we can infer that tapering implants provide greater apical bone coverage and reduced fenestration than parallel implants at all potential implant sites in the maxilla. We can also report that long term, a high proportion of implants placed in the maxilla do not have optimal bone coverage.

Future CBCT imaging studies investigating the morbidity of dental implants, especially in regions of high esthetic value (e.g. guided vs. non-guided placement) should

be prospective providing baseline data. Equipment and implant specific imaging protocols including voxel size exposure parameters and use of metallic artifact reduction software should be developed. Imaging correlation studies between actual and radiographic FAB are suggested.

CHAPTER VI

CONCLUSION

For implants placed long term in the anterior maxilla, approximately 55% show no FAB_r at the level of the implant/abutment interface. The mean FAB_r covering dental implants in the anterior maxilla is less than 1mm in the cervical half of the implant at all sites irrespective of type. FAB_r coverage of implants in the anterior maxilla is greater in the apical half of as compared to the cervical half (p=0.04). Tapered implants have greater FAB_r coverage in the apical region than parallel implants (p=0.04). Females demonstrate significantly less bone (approximately 0.5mm) in the amount of FAB_r covering the middle third of the implant.

REFERENCES

- Ardaropoli G, Lekholm U, Wennstrom JL. (2006). Tissue alterations at implant-supported single-tooth replacements: a 1-year prospective clinical study. *Clin Oral Implants Res.*17:165–171.
- Benavides E, Rios HF, Ganz SD, An CH, Resnik R, Reardon GT, Feldman SJ, Mah JK, Hatcher D, Kim MJ, Sohn DS, Palti A, Perel ML, Judy KW, Misch CE, Wang HL. (2012). Use of Cone Beam Computed Tomography in Implant Dentistry: the International Congress of Oral Implantologists consensus report. *Implant Dent.* 21:78-86
- Bornstein, M. M., B. Al-Nawas, U. Kuchler and A. Tahmaseb (2014). "Consensus Statements and Recommended Clinical Procedures Regarding Contemporary Surgical and Radiographic Techniques in Implant Dentistry." *Int J Oral Maxillofac Implants* 29(Supplement): 78-82.
- Bouserhal, C., Jacobs, R., Quirynen, M., van Steenberghe, D. (2002). Imaging Technique Selection for the Preoperative Planning of Oral Implants: A Review of the Literature. *Clinical Implant Dentistry and Related Research.* 4:156-72.
- Buser D, Martin W, Belser UC. (2004). Optimizing esthetics for implant restorations in the anterior maxilla: anatomic and surgical considerations. *Int J Oral Maxillofac Implants.* 19 Suppl:43-61.
- Chang M, Wennstrom JL, Odman P, *et al.*,. (1999). Implant supported single-tooth replacements compared to contralateral natural teeth. Crown and soft tissue dimensions. *Clin Oral Implants Res.* 10:185–194.
- Frederiksen, N.L.L. (1995). Diagnostic Imaging in Dental Implantology. *Oral Surg Oral Med Oral Pathol Oral Radiol Endod Oral Surgery, Oral Medicine, Oral Pathology, Oral Radiology & Endodontics.* 80: 540-54.
- Chen S, Buser D, Cordaro L (2008) Chapter 4.1. Principles of Surgical Classification. In: *The SAC Classification in Implant Dentistry* Dawson A, Chen S eds. Quintessence Publishing Co., Ltd. Berlin, Germany. Pp. 28

- Dave, M., J. Davies, R. Wilson and R. Palmer (2012). "A comparison of cone beam computed tomography and conventional periapical radiography at detecting periimplant bone defects." *Clin Oral Implants Res.* 24(6):671-8.
- Degidi M, Nardi D, Daprile G, Piattelli A. (2012). Buccal bone plate in the immediately placed and restored maxillary single implant: a 7-year retrospective study using computed tomography. *Implant Dent.* 21(1):62-6.
- Degidi M, Daprile G, Nardi D, Piattelli A. (2013). Buccal bone plate in immediately placed and restored implant with Bio-Oss(®) collagen graft: a 1-year follow-up study. *Clin Oral Implants Res.* 24(11):1201-5.
- De Rouck T, Collys K, Cosyn J. (2008). Immediate single tooth implants in the anterior maxilla: a 1-year case cohort study on hard and soft tissue response. *J Clin Periodontol.* 35:649–657.
- Evans CD, Chen ST. (2008). Esthetic outcomes of immediate implant placements. *Clin Oral Implants Res.* 19:73–80.
- Frederiksen, N.L.L. (1995). Diagnostic Imaging in Dental Implantology. *Oral Surg Oral Med Oral Pathol Oral Radiol Endod Oral Surgery, Oral Medicine, Oral Pathology, Oral Radiology & Endodontics.* 80: 540-54.
- Grunder U. (2000). Stability of the mucosal topography around single-tooth implants and adjacent teeth: 1-year results. *Int J Periodont Restorative Dent.* 20:11–17.
- Harris, D., D. Buser, K. Dula, K. Grondahl, D. Haris, R. Jacobs, U. Lekholm, R. Nakielny, D. van Steenberghe, P. van der Stelt and O. European Association for (2002). "E.A.O. guidelines fo the use of diagnostic imaging in implant dentistry. A consensus workshop organized by the European Association for Osseointegration in Trinity College Dublin." *Clin Oral Implants Res* 13(5): 566-570.
- Harris, D., K. Horner, K. Grondahl, R. Jacobs, E. Helmrot, G. I. Benic, M. M. Bornstein, A. Dawood and M. Quirynen (2012). "E.A.O. guidelines for the use of diagnostic imaging in implant dentistry 2011. A consensus workshop organized by the European Association for Osseointegration at the Medical University of Warsaw." *Clin Oral Implants Res.* 23(11):1243-53.
- Jemt T, Ahlberg G, Henriksson K, *et al.*,. (2006). Changes of anterior clinical crown height in patients provided with single implant restorations after more than 15 years of follow up. *Int J Prosthodont.* 19:455–461.
- Kan JY, Rungcharassaeng K, Umezu K, Kois JC. (2003). Dimensions of peri-implant mucosa: An evaluation of maxillary anterior single implants in humans. *J Periodontol.* 4:557–562.

- Kan JY, Rungcharassaeng K, Lozada J. (2003). Immediate placement and provisionalization of maxillary anterior single implants: 1-year prospective study. *Int J Oral Maxillofac Implants.* 18:31–39.
- Kois JC. (2001) Predictable single tooth peri-implant esthetics: Five diagnostic keys. *Compend Contin Educ Dent.* 22:199–206.
- Le BT, Borzabadi-Farahani A. (2012). Labial bone thickness in area of anterior maxillary implants associated with crestal labial soft tissue thickness. *Implant Dent.* 21(5):406-10.
- Misje K, Bjørnland T, Saxegaard E, Jensen JL. (2013). Treatment outcome of dental implants in the esthetic zone: a 12- to 15-year retrospective study. *Int J Prosthodont.* 26(4):365-9.
- Miyamoto Y, Obama T. (2011). Dental cone beam computed tomography analyses of postoperative labial bone thickness in maxillary anterior implants: comparing immediate and delayed implant placement. *Int J Periodontics Restorative Dent.* 31(3):215-25.
- Pittayapat, P., D. Galiti, Y. Huang, K. Dreesen, M. Schreurs, P. C. Souza, I. R. RubiraBullen, F. H. Westphalen, R. Pauwels, G. Kalema, G. Willems and R. Jacobs (2013). "An in vitro comparison of subjective image quality of panoramic views acquired via 2D or 3D imaging." *Clin Oral Investig* 17(1): 293-300.
- Roe P, Kan JY, Rungcharassaeng K, Caruso JM, Zimmerman G, Mesquida J. (2012). Horizontal and vertical dimensional changes of peri-implant facial bone following immediate placement and provisionalization of maxillary anterior single implants: a 1-year cone beam computed tomography study. *Int J Oral Maxillofac Implants.* 27(2):393-400.
- Scarfe, W., A. Farman and J. Ruskin (2012). "Is Cone Beam Computed Tomography really necessary for performing Dental Implant Surgery." *Forum Implantologicum* 8(1): 10.
- Spray JR, Black CG, Morris HF, Ochi S. (2000). The influence of bone thickness on facial marginal bone response: stage 1 placement through stage 2 uncovering. *Ann Periodontol.* 5(1):119-28.
- Tyndall DA, Brooks SL. (2000). Selection Criteria for Dental Implant Site Imaging: A Position Paper of the American Academy of Oral and Maxillofacial Radiology. *Oral Surg Oral Med Oral Pathol Oral Radiol Endod.* 89:630-7.
- Tyndall DA, Price JB, Tetradis S, Ganz SD, Hildebolt C, Scarfe WC. (2012). Position Statement of the American Academy of Oral and Maxillofacial Radiology on Selection Criteria for the Use of Radiology in Dental Implantology with Emphasis on Cone Beam Computed Tomography. *Oral Surg Oral Med Oral Pathol Oral Radiol.* 113:817-26.

- Vazquez, L., N. Saulacic, U. Belser and J. P. Bernard (2008). "Efficacy of panoramic radiographs in the preoperative planning of posterior mandibular implants: a prospective clinical study of 1527 consecutively treated patients." *Clin Oral Implants Res* 19(1): 81-85.
- Vera C, De Kok IJ, Chen W, Reside G, Tyndall D, Cooper LF. (2012). Evaluation of post-implant buccal bone resorption using cone beam computed tomography: a clinical pilot study. *Int J Oral Maxillofac Implants*. 27(5):1249-57.
- Worthington, P., J. Rubenstein and D. C. Hatcher (2010). "The role of cone-beam computed tomography in the planning and placement of implants." *J Am Dent Assoc* 141 Suppl 3: 19S-24S.

CURRICULUM VITA

Name: Deepika Joshi

Address: 1011 La Fontenay ct, Louisville, KY- 40217

DOB: November 8, 1988

Education and Training:

- Bachelor of Dental Surgery (B.D.S)

MNR Dental College

2007-2012

- Master's in Oral Biology

University of Louisville, School of Dentistry

2013-2016

Poster presentations:

- Poster: Long term follow up of buccal alveolar bone wall changes associated with endosseous implants

2014

Guided by: Scarfe WC, Azaevedo BD, Department of Surgical/Hospital

Dentistry, University of Louisville School of Dentistry

- Poster: Flap surgery in Periodontics

Guided by: Dr. Anuradha, Professor, Department of Periodontics,

MNR Dental College,

2010.